

എ.എം.എ.എ. തൃശ്ശൂർ സോൺ കമ്മിറ്റി സംഘടിപ്പിച്ച My Success Story ചികിത്സാനുഭവ സമാഹരണങ്ങളിൽ നിന്നും ആദ്യത്തെ 10 മികച്ച ചികിത്സാനുഭവങ്ങളിൽ ഒന്നായി തിരഞ്ഞെടുക്കപ്പെട്ടത്.

Prachanam followed by Durdhurapathra swarasa lepa in the management of Alopecia Areata (Indraluptha): A case report



Dr. Priyanka K.V
BAMS, MD (Ay),
Assistant Professor
Department of Agadatantra
SRAMCH, Malladihalli, Karnataka.

Name: T. Shambhunath

Address: Pattazhi, Thiruvananthapuram

Age/Sex: 22/M

Presenting complaints with Duration:

1. C/O Loss of hair in single circular patch in diameter of 3.5 cm from the back of scalp.
2. C/O Generalized hairloss. Duration: 6 weeks

This was a case report of a 22 year old male patient from pattazhi, who reported on 11/2/2021 in Agadatantra OPD of Government Ayurveda College, Thiruvananthapuram with the chief complaints of asymptomatic loss of hair at the vertex for 6 months. Hair loss was circular in pattern, as it was more obvious at the center and spreading to the periphery. There was no history of similar illness in family members & he has no history of any other systemic illness and intake of drugs. But his mother had history of psoriasis and he was very stressed due to personal issues. On examination, only a single circular patch of nonscarring alopecia of 3.5cm diameter with SALT score 6 distributed on occipital & parietal area of scalp. The area was smooth, shiny & spongy with no associated skin changes.

Other systemic examinations were within normal limits. Potassium hydroxide (KOH) examination of hair showed no fungal elements. On hand lens examination, total number of follicles were reduced, but few follicular ostia were found. On the basis of clinical examination & KOH test, the diagnosis of Alopecia areata was made. Before the commencement of treatment protocol, basic blood investigations were done.

On 11/2/2021

Hb- 15.1g%

TRBC- 4.6 million/cmm

TWBC- 8600 cells/cmm

ESR – 8 mm at 1 hr

T. Platelet count- 3.44

AEC – 430 cells/cmm

FBS – 101 mg%

T. Cholesterol – 135 mg%

Ca – 9.7mg%

TSH- 1.08 milli IU/l

All are within normal limit with slight variation in AEC. The patient was subjected for following treatments.

- 20 gm Mahathikthakam gritham at 7 A.M and 4 P.M in empty stomach with ¼ glass of warm water as anupana for 7 days.

- Ushnambusnana after self abhyangam with warm balatailam in morning for 3days.

- 25 gm of Avipathy choornam with sufficient quantity of honey at 6 A.M in empty stomach. Advised to take hot water in small quantities intermittently. After the completion of vegas and attaining proper appetite, they were advised to take gruel or light food.

- After attaining samyak sodhana they were advised to take Samsarjana karma for the

following 4days.

- On 16th day patient was advised to take Sadhyasnehana, by giving peya mixed with 50ml plain ghee and 3gm saindhavam at 6pm.

- On 17th day at our OPD, Prachanam done (after checking RTPCR for COVID 19). When bleeding stops, applied juice of Durdhoorapathra on the affected area for 30 minutes.

- After 30 minutes the area cleaned with Thriphala kashayam.

- Patient was observed for next 30mnts and gave 1 glass of boiled milk with sugar (prabhootha sita) as antidote.

Advices

- Avoid bathing of head & application of oil on that day.

- Apply juice of Durdhoorapathra on the affected area for 30 minutes for the next 7days.

- Follow the pathya apathya strictly

Avoid head bath for 3days following kuttanam.

Avoid intake of katu, amla and lavana aharas, especially lavana

Take plenty of water.

Include tilam, leafy vegetables, fruits, jaggery, milk etc in food.

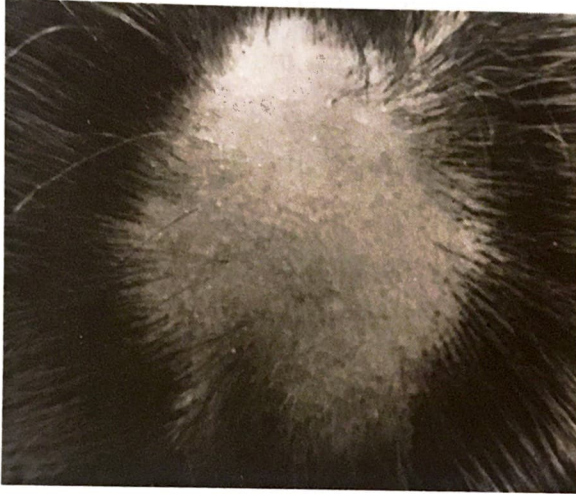
Do meditation or pranayama daily for 30 minutes.

- After 7 days adviced to take 10 gm of Narasimha rasayanam with ¼ glass of warm water as anupanam in empty stomach at 6am for 1 month.

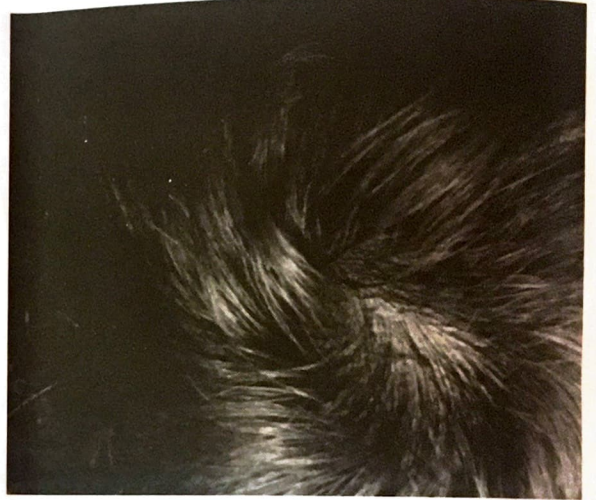- Apply Malathyadi keram with Indralupthamashi over the site for following days. (Almost 1 month)
- Symptomatic managements were given, on reviewing.

was aimed at revalidating them for suffering young generation affected with Alopecia areata. Ayurveda has a lot of miraculous treatment. But all of them are not revealed yet, or not widely practicing yet. During

B/T (11/2/2021)



After 3 months



Observations

Result: Area completely filled with new hairs and SALT score became zero. Patient was satisfied and feels better.

CONCLUSION

The treatment protocol used in this case study were validated formulations of Ayurveda as per the classics. This attempt

the course of treatment, patient didn't feel any side effects or worsening of condition. And further appearance of lesions was not noticed. Generalized and localized purification procedures may be eliminating the toxic contents in the body and reduces the triggering factors of the immune system. Ayurveda is not a magical remedy even though it can show wonders.